

Ultrasound in clinical practice: What, how, why, when and where?

Joanne Cleland & Jodi Allen

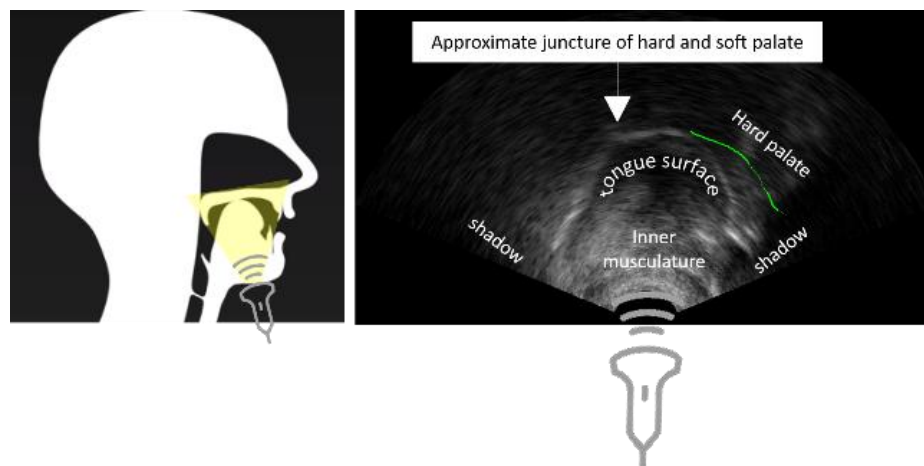
Twitter: :DrJoanneCleland, @JodiAllenSLT, @SlitUltrasound, @CSDRNetwork

The use of ultrasound imaging in speech and language therapy (SLT) practice is an area of rapid growth. As evidence for its use increases across the profession, those wishing to explore integration into practice have raised important questions such as: Who is currently using ultrasound? Why might I use it in my practice? Where would I source the equipment? What are the training requirements?

What is ultrasound?

Ultrasound is sound waves beyond the range of human hearing. In medical ultrasound, these waves are emitted from a probe into the body and the returning echo is converted to an image. Ultrasound is therefore a reflection (or echo), not a photographic image. This distinction is important as ultrasound images contain 'artefacts' which can make them challenging to analyse. Soft tissue structures absorb and reflect sound waves at different frequencies. This makes ultrasound ideal for imaging head and neck anatomy such as the tongue, floor of mouth muscles, vocal folds and salivary glands. Sound waves don't pass through bone, therefore anything beyond these structures will be in a dark shadow. For this reason, it is not possible to view structures such as the hard palate (Cleland, 2021), however shadows from structures such as the hyoid bone or mandible can be used as a landmark. Figure one shows an ultrasound image of the tongue between the shadow of the hyoid (left) and shadow of the mandible (right).

Figure 1: Left MRI diagram showing approximate positioning of ultrasound probe. Right: Typical ultrasound image of the tongue.

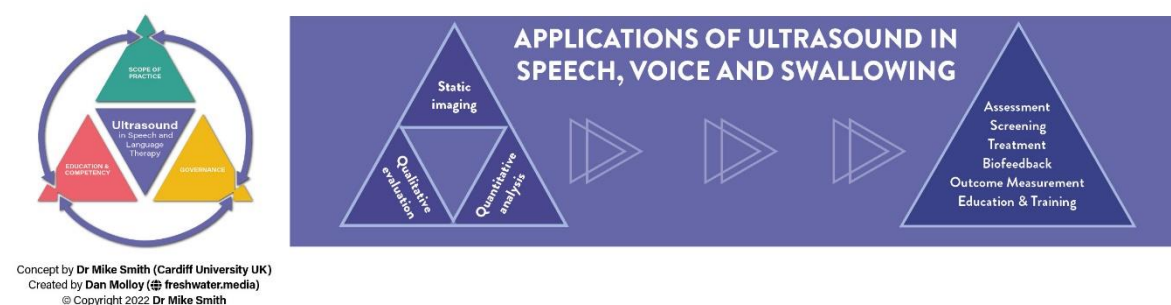

Who is using ultrasound and how does it translate to SLT practice?

Sonographers are allied health professionals (AHPs) specifically trained in imaging and use ultrasound as a diagnostic tool. Other AHPs such as physiotherapists, also use ultrasound to augment certain aspects of their practice (Strike et al., 2022). At the end of last year we worked together with a physiotherapist, Mike Smith at Cardiff University, to outline an initial framework for use of ultrasound in SLT practice (Allen et al., 2022). To do this, we first summarised the range of

clinical applications across speech, voice and swallowing. The framework and areas of application in SLT are shown in figure two.

Figure 2: Framework for the use of ultrasound in SLT practice



Why would I use ultrasound in my practice?

In some areas of practice, the evidence base is reasonably well established, but others remain in the research domain. For example, use of ultrasound for real-time for biofeedback treatment of speech sound disorders has been possible since the 1980s (Sugden et al., 2019). Despite initial slow adoption due to technology and cost constraints, it is now used regularly in cleft lip and palate care in Glasgow and some other paediatric community services across Scotland. In this context, ultrasound has replaced more costly or invasive instrumental techniques and/or offers better intervention outcomes (Sugden et al., 2019). Use of ultrasound to guide Botulinum toxin injection for patients with sialorrhea is also well-established (Loens et al., 2020) and SLTs in some areas of the UK are now acquiring competence to do this. In contrast, use of ultrasound for the assessment and diagnosis of dysphagia, whilst showing promise in research, needs further research to ensure its validity and reliability (Allen, Clunie, & Winiker, 2021). Use of ultrasound for qualitative evaluation of vocal fold movement has shown good specificity and sensitivity in the post-surgical population (Allen, Clunie, Slinger, et al., 2021) and evaluating its utility in the neurological population is currently underway in a pilot study in London (see <https://beta.clinicaltrials.gov/study/NCT05493397>).

What Equipment do I need & where can I get it?

One of the appeals of ultrasound is that once you have the equipment, you can use it for as many clients as appropriate without many ongoing costs. That said, the initial equipment outlay may be expensive. For SLTs working in acute settings it may be possible to borrow equipment from other departments, as long as they have suitable probes. High frequency linear probes tend to be used for viewing vocal fold movement and superficial structures like the floor of mouth, whereas lower frequency convex probes are used for viewing swallowing physiology such as tongue and hyoid movement. Similar considerations are needed for working with children's speech sound disorders, though a smaller (20mm) convex, or a microconvex probe will give the best image. Speech (and to some extent voice) work comes with the added complication that if you want to make an audio recording, useful for both monitoring progress and providing delayed feedback, then you need to synchronise the audio and ultrasound. In the clinics in Scotland we use a commercial system which automatically records and synchronises the audio and ultrasound. It comes with software for setting up wordlists and providing biofeedback therapy. This system is portable and costs around £4K. Hospital-based consoles are much larger and more expensive. Hand-held android-compatible

systems are cheaper and portable but should not be used for diagnosis or assessment until research shows better reliability (Winiker et al., 2021).

What are the key considerations before I use the ultrasound with clients?

Ultrasound imaging is a non-regulated imaging modality. This means there are no legal considerations for SLTs in using it, as long as it is used appropriately. Our scope of practice includes not just what you are imaging, but what you do with that information from the perspective of clinical decision making. As SLTs we image structures of the head and neck, but only those relevant to speech, voice and swallowing. It's essential that these aspects are already within our area of expertise before augmenting them with ultrasound imaging. For example, imaging for the purpose of identifying cysts and tumours would not be in our scope of practice, but imaging to identify the muscle size and structure(s) of the floor of mouth might be. It is possible that when imaging a client you might see something that concerns you. For example, whilst analysing data at Strathclyde university, researchers spotted an unusual dark area in the floor of a five-year-old girl's mouth. As such, clear protocols for raising concerns such as this need to be in place: in this case the child was under the care of the hospital cleft team who arranged a more specialised scan, later diagnosed a cyst and referred for surgery. Cases like this highlight the benefits of working in a multidisciplinary team.

How much training do I need?

Ultrasound images are hard to acquire and interpret, especially when you are new to them. You will need to practice your skills in positioning the probe, using the equipment to optimise your image and interpret them. At the moment certified courses for SLTs are not available, although there is potential for this should demand increase. Those currently skilled in ultrasound have either had research training and/or one-to-one mentorship from a sonographer working in this area. This sort of training, plus access to supervision or support from colleagues is important to develop and maintain competence. For those wanting to explore aspects of SLT-related ultrasound in more detail, some online materials are available, for example <https://swallow-vision.com/> for those interested in dysphagia, and <https://seeingspeech.ac.uk/> for those who want to view typical tongue movements during speech. An open access training manual is available for biofeedback speech treatment (Cleland et al., 2018), and a new website with ultrasound examples of disordered speech is due to be launched in Summer 2023. If you would like hands-on training then please do contact us to register your interest.

What are the governance issues?

RCSLT considers ultrasound to be an extended scope of practice. This means that you are insured via your RCSLT membership, though each case is evaluated on its own merits. As with all aspects of SLT practice, clinicians need to work within their level of competence and have local governance arrangements in place, including support from your manager and a clear care pathway. Quality assurance is important. Peer-review of images and written reports will be important when ultrasound is used for assessment purposes. Importantly, SLTs are encouraged to remember that ultrasound is simply another tool in your toolbox. Your level of competency within your clinical area will determine your effectiveness with ultrasound imaging.

What is the future of ultrasound in SLT practice?

The UK is at the forefront of clinical research in ultrasound imaging for SLT. Ongoing work includes technological developments to enable more precise measures to be taken from ultrasound images,

use of ultrasound to assess underlying muscle structure in clients with dysphagia, and a clinical trial of ultrasound biofeedback therapy for clients with cleft lip and palate. We hope that clinicians will feel empowered to try using ultrasound and to form a community of practice in this area.

Top Tips

1. Connect with researchers and experienced clinicians who are already using ultrasound for advice, support and development of competence.
2. Practice imaging people who do not have speech, voice or swallowing disorders so you get to know the range of normal anatomy and gain some experience in using the equipment.
3. Keep up to date with the ever-evolving research literature in SLT ultrasound.

Suggested wording for ultrasound reports.

Aligning with the scope of clinical and sonographic practice outlined for SLTs performing US (Allen et al., 2023) this scan is undertaken for the purposes of assessing/treating XXX as an adjunct to XXX as part of SLT management. The identification of other anatomical or pathological elements is explicitly beyond the scope of practice of the clinician. Therefore, the scan cannot be relied upon to either confirm or exclude any such anatomical or pathological elements.

References

- Allen, J. E., Cleland, J., & Smith, M. An initial framework for use of ultrasound by speech and language therapists in the UK: Scope of practice, education and governance. *Ultrasound*, 0(0), 1742271X221122562. <https://doi.org/10.1177/1742271x221122562>
- Allen, J. E., Clunie, G. M., Slinger, C., Haines, J., Mossey-Gaston, C., Zaga, C. J., Scott, B., Wallace, S., & Govender, R. (2021). Utility of ultrasound in the assessment of swallowing and laryngeal function: A rapid review and critical appraisal of the literature. *International Journal of Language & Communication Disorders*, 56(1), 174-204. <https://doi.org/https://doi.org/10.1111/1460-6984.12584>
- Allen, J. E., Clunie, G. M., & Winiker, K. (2021). Ultrasound: an emerging modality for the dysphagia assessment toolkit? *Current Opinion in Otolaryngology & Head and Neck Surgery*, 29(3), 213-218. <https://doi.org/10.1097/moo.0000000000000708>
- Cleland, J. (2021). Ultrasound tongue imaging. In *Manual of clinical phonetics* (pp. 399-416). Routledge.
- Cleland, J., Wrench, A., Lloyd, S. & Sugden, E. (2018) *ULTRAX2020 : Ultrasound Technology for Optimising the Treatment of Speech Disorders : Clinicians' Resource Manual*. (<https://doi.org/10.15129/63372>)
- Loens, S., Brüggemann, N., Steffen, A., & Bäumer, T. (2020). Localization of Salivary Glands for Botulinum Toxin Treatment: Ultrasound Versus Landmark Guidance. *Movement Disorders Clinical Practice*, 7(2), 194-198. <https://doi.org/https://doi.org/10.1002/mdc3.12881>
- Strike, K., Chan, A. K. C., Maly, M. R., Newman, A. N. L., & Solomon, P. (2022). Physiotherapist Performed Point of Care Ultrasonography (POCUS): A Scoping Review of 209 Studies. *Physiotherapy*. <https://doi.org/https://doi.org/10.1016/j.physio.2022.11.005>

- Sugden, E., Lloyd, S., Lam, J., & Cleland, J. (2019). Systematic review of ultrasound visual biofeedback in intervention for speech sound disorders. *International Journal of Language & Communication Disorders*, 54(5), 705-728. <https://doi.org/10.1111/1460-6984.12478>
- Winiker, K., Burnip, E., Gozdzikowska, K., Hernandez, E. G., Hammond, R., Macrae, P., Thomas, P., & Huckabee, M.-L. (2021). Ultrasound: Reliability of a Pocket-Sized System in the Assessment of Swallowing. *Journal of Speech, Language, and Hearing Research*, 64(8), 2928-2940. https://doi.org/doi:10.1044/2021_JSLHR-21-00026