

Visualising Speech: Identification of Atypical Tongue-Shape Patterns in the Speech of Children with Cleft Lip and Palate Using Ultrasound Technology

Susan Lloyd¹, Joanne Cleland¹, Lisa Crampin², Linsay Campbell², Natalia Zharkova³, & Pertti Palo¹

¹University of Strathclyde, UK, ²NHS Greater Glasgow & Clyde ³Queen Margaret University, UK

joanne.cleland@strath.ac.uk

@DrJoanneCleland @SusieSpeechie

Background

Gibbon (2004) identifies 8 distinct error types in the speech of people with cleft lip and palate (CLP) using electropalatography (EPG)¹.

EPG measures tongue-palate contact, but is expensive and logistically difficult. In contrast, ultrasound tongue imaging (UTI) is cheaper, and can image the posterior articulations (such as pharyngeals) not visible with EPG which are common in CLP.

⇒ Can the eight error types made visible with EPG in CLP speech¹ also be identified with ultrasound?

Method

To date, data has been collected from 35 children aged 3 to 12 with CLP.

Data are spoken materials from the CLEFTNET protocol²:

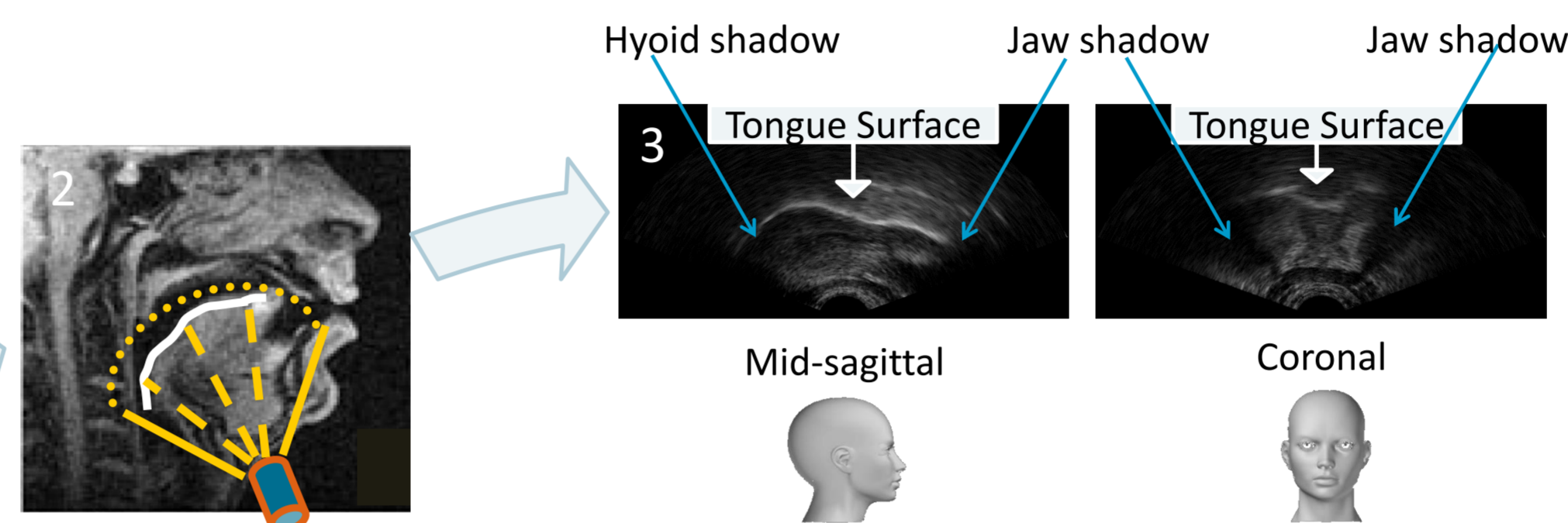
- /aCa/ x 10
- Minimal sets (e.g. a sip, a ship, a kip, a tip)
- Sentences from the GOS.SP.ASS. 98³ (e.g. (Happy) Karen is making a cake)

Analysis using ultrasound-assisted transcription to identify Gibbon's 8 error-types:

- Live by the clinician collecting the data
- Offline but in Real-time by two ultrasound trained clinicians
- Offline in slow motion by two ultrasound trained clinicians

Quantitative Ultrasound Analysis using indices from the literature.

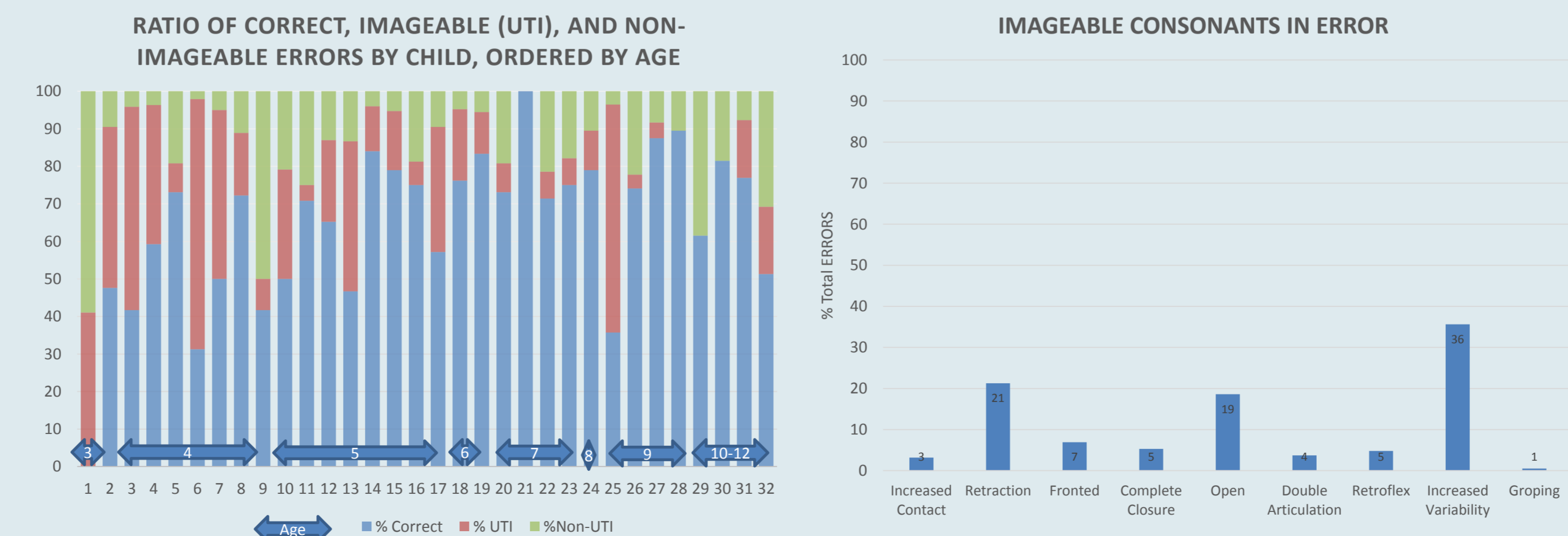
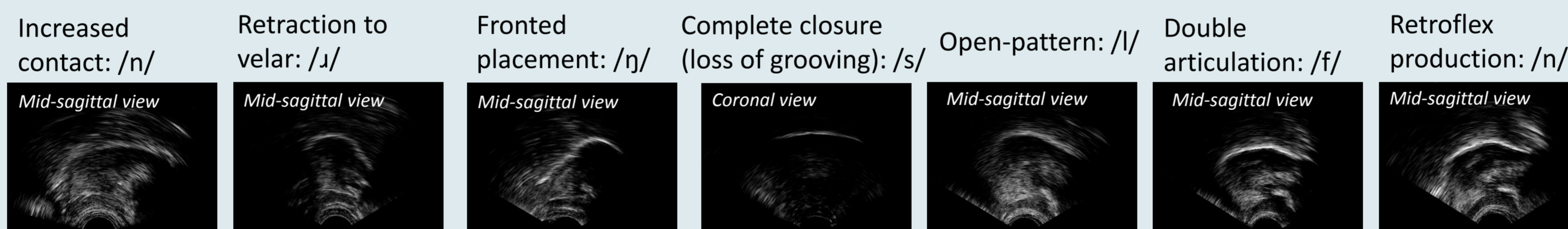
Imaging using Ultrasound



1. Probe stabilised with headset; can be oriented for sagittal or coronal views
2. The tongue is visible from the larynx to the tongue tip in mid-sagittal view
3. Bone does not image on ultrasound, so the image is bordered by two shadows: the hyoid and front of the jaw in mid-sagittal view, and the two sides of the jaw in coronal view

Results: Errors Revealed by Ultrasound

Target sounds indicated in /brackets/. Mid-sagittal views show the tongue tip to the right. Abnormal timing and increased variability are also identifiable with UTI, but not shown here.



Results: Aided Transcription

From early analysis of data gathered so far:

- 60.3% of consonants were produced correctly
- 60.1% of consonants in error were imageable by ultrasound
- Non-imageable errors were non-lingual: e.g. nasalised, fricated/loss of pressure, glottal reinforcement

Inter-rater reliability for offline real-time transcription was "good" using Cohen's kappa ($k=.716, p<.0005$).

Discussion

- All of Gibbon's errors have been identified in our data using ultrasound aided transcription
- Additionally, retroflex errors were identified using UTI
- Identification of some error types may change diagnosis and therefore intervention choice
- Ultrasound is cheaper and more convenient than EPG as it does not require individualised plates or advance planning: children were able to opt in to the project while at routine appointments

References

¹Gibbon, F. (2004). Abnormal patterns of tongue-palate contact in the speech of individuals with cleft palate. *Clinical linguistics & phonetics*. 18. 285-311.

²Gibbon, F., Crampin, L., Hardcastle, B., Nairn, M., Razzell, R., Harvey, L., Reynolds, B. (1998). CLEFTNET (Scotland): A Network for the Treatment of Cleft Palate Speech Using EPG. *International Journal of Language & Communication Disorders* 33(sup1): 44-49.

³Sell, D., Harding, A., Grunwell, P. (1999). GOS.SP.ASS '98: an assessment for speech disorders associated with cleft palate and/or velopharyngeal dysfunction (revised). *International Journal of Language & Communication Disorders* 34(1):17-33.