

# The Diabetic Retinopathy Screening Workflow: Potential for Smartphone Imaging

---

Mr. Nigel M. Bolster (MEng)<sup>\*1</sup>

nigel.bolster@strath.ac.uk

Dr. Mario E. Giardini (PhD)<sup>1</sup>

mario.giardini@strath.ac.uk

Dr. Andrew Bastawrous. (BSc (Hons) MBChB HFEA MRCOphth. Clinical Lecturer in  
International Eye Health)<sup>2</sup>

andrew.bastawrous@lshtm.ac.uk

\* Corresponding author

<sup>1</sup> Department of Biomedical Engineering, University of Strathclyde, Glasgow, G4  
0NW, UK

<sup>2</sup> International Centre for Eye Health (ICEH), Clinical Research Department, Faculty of  
Infectious & Tropical Diseases, London School of Hygiene & Tropical Medicine,  
Keppel Street, London, WC1E 7HT, UK

## List of Abbreviations

DM - diabetes mellitus

DR – diabetic retinopathy

DMac – diabetic maculopathy

LMIC – low- and middle-income country

FoV – field-of-view

Pixel – picture element

## Keywords

diabetic retinopathy, fundoscopy, mHealth, ophthalmoscopy, smartphone, telemedicine

5 figures and 0 tables

Some material requires permissions (Figures 2 and 4).

Some material has been reproduced under Creative Commons Licenses (Figures 1 and 3)

## Abstract

Complications of diabetes mellitus, namely diabetic retinopathy and diabetic maculopathy, are the leading cause of blindness in working aged people. Sufferers can avoid blindness if identified early via retinal imaging. Systematic screening of the diabetic population has been shown to greatly reduce prevalence and incidence of blindness within the population. Many national screening programmes have digital fundus photography as their basis.

In the past five years several techniques and adapters have been developed that allow digital fundus photography to be performed using smartphones. We review recent progress in smartphone-based fundus imaging and discuss its potential for integration into national systematic DR screening programmes.

Some systems have produced promising initial results with respect to their agreement with reference standards.

However further multi-site trialling of such systems' use within implementable screening workflows is required if an evidence base strong enough to affect policy change is to be established. If this were to occur national diabetic retinopathy screening would, for the first time, become possible in low- and middle-income settings where cost and availability of trained eye-care personnel are currently key barriers to implementation. As diabetes prevalence and incidence is increasing sharply in these settings, the impact on global blindness could be profound.

## Introduction

Diabetic retinopathy (DR) and diabetic maculopathy (DMac) are the leading causes of blindness in high-income settings for those aged between 20 and 74 years [1]. As the most common microvascular complications of diabetes mellitus (DM), they are also increasingly becoming a major cause of blindness in low- and middle-income countries (LMICs) as DM prevalence and incidence in these settings has risen sharply in recent years [2].

Although the development of sight-threatening complications of DM can be delayed by appropriate treatment of systemic diseases such as DM itself, high blood pressure and lipid metabolism abnormalities [3], nearly all type 1 DM patients and 60% type 2 patients develop DR or DMac [4]. If the disease progresses to a stage where direct intervention is necessary, laser treatment or intravitreal injection of steroid or anti-vascular endothelial growth-factor (anti-VEGF) agents are often successful in preserving vision [4]. In each case, early diagnosis is crucial to the success of the treatment [5].

Diagnosis of DR and DMac is commonly achieved by imaging the fundus either by retinal photography, by direct or indirect ophthalmoscopy, or by slit lamp biomicroscopy [6]. Given the criticality of early diagnosis, opportunistic diagnosis of DR during routine eye examinations is insufficient. Consequently, many countries have adopted systematic screening programmes within their DM populations in order to reduce the numbers of people developing blinding disease [7-11]

## Development of the Diabetic Retinopathy Screening Workflow

In 1980 Iceland became the first country to introduce nationwide, systematic retinal screening amongst patients with DM [7]. Approximately 90% of the country's several hundred insulin-treated diabetic patients were examined on an annual or

biennial basis, at Iceland's single diabetes clinic [12]. During each patient visit eye and general health histories were first reviewed, followed by visual acuity measurements. An examination of the posterior segment would then be conducted by an ophthalmologist specialising in retina with the posterior pole being examined by slit lamp biomicroscopy and the peripheral retina being examined by indirect ophthalmoscopy. Colour photographs of the fundus would also be taken during each visit. Macular laser treatment or panretinal photocoagulation would then be performed as appropriate [13]. The result of this programme has been the reduction of the prevalence of blindness within the diabetic population from 2.4% to 0.5% [14].

In the United Kingdom, every DM patient over the age of twelve is offered an annual retinal examination. As the UK has a diabetic population of close to 2 million people [8], a different screening approach to that of the Icelandic model has been adopted. During each patient visit a medical history is taken (although this is not used for referral decisions), visual acuity is assessed and 45° field digital images of each fundus are photographed under dilation [15]. The fundus images are then forwarded to a grading centre for grading by an experienced grader holding the appropriate vocational qualification [16]. All images graded abnormal and 10% of those graded normal are independently graded by a second grader. Only if the graders disagree is the image subsequently forwarded to an ophthalmologist specialising in retina. Patients who are found to have no visible maculopathy and either no visible or only background retinopathy are asked to return the following year for rescreening whilst unclassifiable patients and those with other grades of disease are referred to an eye clinic [15]. In contrast to the Icelandic model, this workflow does not require each patient to be examined by an ophthalmologist nor does it involve biomicroscopy or indirect ophthalmoscopy during the initial

screening stage. The model therefore more readily lends itself to the deployment of non-hospital based clinics, such as mobile clinics or eye screening clinics based within primary care centres. These have been shown to increase screening effectiveness in rural and remote settings as well as being a more cost-effective means of detecting DR compared to classical techniques [17]. Predominantly as a result of nationwide screening, DR is no longer the leading cause of blindness amongst working-age adults in the UK, having been so for at least 50 years [18]. Similar screening workflows have been adopted in several other European nations keen to also reduce DR-related blindness [9-11].

Additionally, automated screening algorithms have begun to be incorporated into the national DR screening programme in Scotland, U.K. [19]. These offer the potential to screen out the bulk of healthy, and most time consuming to assess, images before a human retinal screener needs to be involved [20]. This requires a workflow where digital fundus photography is used during the first stage of screening.

It should be noted that although the majority of diabetes sufferers live in LMICs, where nationwide DR screening and care has thus far not been effectively implemented, with only rudimentary detection and management existing in many countries [21]. Barriers to effective DR care implementation include: few ophthalmologists trained in DR management, lack of fundoscopy training for eye health workers including opticians and ophthalmic clinical officers, poorly functioning referral systems from primary to secondary care, little access to imaging technology, lack of treatment infrastructure such as properly maintained lasers, and a lack of relevant national policies [21].

## Diabetic Retinopathy Screening Requirements for Digital Photography

The advancement of DR grading using digital fundus images has been reviewed in detail elsewhere [22]. Modern digital camera sensors have exceeded the resolution of traditional 35-mm film [23] and digital fundus cameras have superseded their film predecessors. However, the quality of the image formed on the detector is also affected by aberrations within the camera optics, distortion, field curvature and is ultimately limited by diffraction. It is such factors that limit the image quality of modern digital cameras rather than the sensor resolution (pixel count – “megapixels”), which is nevertheless frequently provided as a sole measure of digital camera quality by manufacturers and in some peer-reviewed literature. Appropriate assessment of a fundus camera’s optical quality is achieved by using a specially designed test target (USAF 1951 resolution test chart, shown in Figure 1) to determine its resolving power, measured in line pairs per mm (lp/mm). This involves finding the minimum resolvable separation of a set of three parallel black lines, with a width equal to their separation, on a white background [24]. The current international standard for fundus cameras specifies a lower limit of 80 lp/mm in the image centre to 40 lp/mm at the periphery for a field-of-view (FoV) of 30° or less and 60 lp/mm to 25 lp/mm for a FoV greater than 30° [25].

The continued increase in the quality of smartphones’ embedded cameras is therefore of interest, with recent handsets capturing images with quality comparable to those of compact digital cameras. Today’s handsets can also record high-quality videos at 1080p (1920 x 1080 pixels per frame) high-definition resolution, and even 4K (4096 x 2160 pixels per frame) ultra-high-definition resolution, in the case of some high-end devices.

However, as noted above, image quality relies on a host of parameters besides sensor pixel count. The engineering challenges in building quality camera optics within a mobile phone are substantial. The requirement to be low-cost and capture a wide variety of scenes necessitates plastic lenses suitable for mass production and an aperture with a fixed diameter. Also the whole camera module needs to be thin, limiting the allowed space between optical components. Finally, as with any digital camera, how the image is encoded and compressed after acquisition can also degrade the image quality.

Nevertheless, in recent years the advancement of smartphone imaging technology has been such that funduscopy systems have begun to emerge using smartphone cameras as the imaging component.

## Smartphone Prevalence

The introduction of smartphones has had a profound impact on mobile connectivity, combining the simple voice and text communication capabilities of their predecessors with more powerful computer processing, an operating system allowing application installation and upgrade, global positioning systems, high-resolution cameras, and a variety of other sensors such as accelerometers and fingerprint scanners [26]. Such is the appeal of this technologically-rich resource that in 2013 it was reported that 65% of US adults owned a smartphone [27].

Medical professionals are certainly no exception with it being reported as early as 2010 that 80% of medical doctors in the UK owned a smartphone [28].

Furthermore, the phenomenon is not confined to high-income settings. For example it was reported in 2014 that in China there is 95% mobile phone ownership and 37% smartphone ownership whilst in Kenya 82% own mobile phones with 1 in 4 of these being a smartphone [29].



Using such a universally available consumer device as the basis of fundus imaging systems may offer a means of removing many of the aforementioned barriers to timely detection and treatment of DR where nationwide screening does not currently exist and significantly lower costs where it does. For this to be realised, the technology must be of sufficient quality and also be capable of integration into the DR workflow. In this paper we review recent progress in smartphone-based fundus imaging and discuss its potential for integration into national systematic DR screening programmes.

## **Review of Smartphone Retinal Imaging Technology**

### **Smartphone Slit Lamp Adapters**

The simplest means of introducing the imaging capabilities of smartphones into retinal imaging workflows is to simply “bolt-on” handsets to existing retinal imaging equipment. Barsam et al. have shown that it is possible to capture good quality anterior segment images by manually aligning the optic of a smartphone (iPhone 3G, Apple Inc., Cupertino, CA, USA) with either eyepiece of a biomicroscope slit lamp (BM 900, Haag-Streit, Köniz, Switzerland) [30]. Although the authors only reported anterior segment images, it was later shown by Gurram et al. that it is possible to capture retinal images by inserting a 90D condensing lens between the patient’s eye and the biomicroscope and aligning the light source with the optical axis [31].

### **Monocular Indirect Ophthalmoscopy**

In 2010 Lord et al. reported a simple method for capturing retinal images similar to classical indirect ophthalmoscopy [32]. This involved holding a 20D lens in-front of the patient’s eye and holding a pen torch and smartphone (iPhone, Apple Inc.) at a distance using the other hand. They found that the smartphone camera would then

autofocus onto the retinal image formed by the lens allowing a digital image to be captured using the phone's stock camera application. As smartphone technology matured and integrated LED flashes became commonplace, the smartphone could itself deliver the necessary co-axial retinal illumination, dispensing with the need to balance a torch alongside the phone, a technique coined "smartphone funduscopy" and shown in Figure 2 [33]. Although this reduced the complexity of the procedure, finding and holding the lens at the correct distance from the eye nevertheless requires a level of skill generally only exhibited by ophthalmologists or trained eye-care personnel.

Ryan et al. compared using this technique with an iPhone 5 (Apple Inc.) to standard three-field non-mydratic and seven-field mydratic retinal photography on 300 pharmacologically dilated diabetic patients [34]. The authors found the sensitivity of the smartphone images to be 81% and 50% compared to each standard respectively and the specificity to be 94% against each standard. They therefore concluded that 20D lens-assisted smartphone photography lacks sufficient sensitivity for detection of DR.

Myung et al. used 3d printing technology to simplify the above procedure. The authors designed the plastic arm shown in Figure 3 which holds the lens at a fixed distance from the camera, allowing the entire system to be held and moved as a single unit [35]. Hong et al. reported a similar, publically available design allowing anyone with access to a 3d printer to build the system [36]. However the distance between the lens and the eye is not fixed and therefore a degree of skill is still required to form the retinal image.

Ophthalmoscope manufacturer Welch Allyn Inc. (Skaneateles Falls, NY, USA) has released a commercially available means of acquiring smartphone images. The

iExaminer adapter for the PanOptic allows retinal images with a 25° subtended angle to be captured using an iPhone 4 or 4S (Apple Inc.) whilst keeping all optical dimensions fixed [37]. Although this is the only such device to achieve U.S. Food and Drug Administration approval to-date, the system, excluding smartphone, retails at over 1000 USD and has not been updated for current handset models, meaning it is now out-of-date with respect to phone models actively on the market [38].

## Direct Ophthalmoscopy

Two adapters that allow smartphones to capture retinal images through direct ophthalmoscopy have since been developed. 'Peek Retina' uses a prism to closely align a light source with the optical axis of the smartphone camera [39] and 'D-Eye' (D-Eye Srl, Padova, Italy) inserts a beam-splitter into the optical path of the camera optics to provide co-axial illumination of the eye using the LED flash [40].

The inventor of D-Eye, shown in Figure 4, and colleagues have reported results from the examination of 240 eyes in 120 out-patients with either type I or type II DM at an ophthalmic diabetic centre (Spedali Civili di Brescia, Italy) [41]. They reported a sensitivity of 0.90 (95% CI 0.82-0.94) and a specificity of 0.96 (95% CI 0.90-0.98) for detection of DR by a retinal specialist when compared to biomicroscopy by a retinal specialist. For grading of DR a simple  $\kappa$  of 0.78 (95% CI 0.71-0.84;  $p < 0.001$ ) was reported and 3.75% of eyes were ungradable with D-Eye compared to 1.7% with biomicroscopy. With respect to detecting significant cystoid macular edema a sensitivity of 0.81 (95% CI 0.57-0.94), a specificity of 0.98 (95% CI 0.95-0.99) and a simple  $\kappa$  of 0.79 (95% CI 0.65-0.93) were reported when compared to biomicroscopy. In each case examinations and assessments were made by retinal specialists only.

To the authors' knowledge, there is presently no peer-reviewed comparison of D-Eye to conventional digital fundus photography, the gold standard and the only means used for the detection in the first stage of many national screening programmes.

Peek Retina has been used in validation studies in LMICs. The device's performance was first compared to a DRS retinal camera (Haag-Streit) nested within a population-based cohort study of eye disease in Nakuru, Kenya [42]. Fundus images of both eyes were taken for 1,328 participants by non-healthcare trained, lay examiners using Peek Retina and by a specialist technician using the retinal camera. These images were then sent to Moorfields Eye Hospital Reading Centre (London, U.K.) for independent grading. The authors reported a weighted kappa of 0.71 when comparing lay examiners using Peek Retina with an ophthalmic technician using the reference desktop camera for optic nerve examination. Bland-Altman analysis demonstrated an average difference of -0.02 with 95% limits of agreement between -0.21 and 0.16 for vertical cup-to-disc ratio assessment, suggesting good agreement between the lay-operated Peek Retina and the reference standard [43].

Peek Retina pre-production prototypes, shown in Figure 5, are presently being trialled alongside standard digital (Topcon NRW6, Topcon Corp., Tokyo, Japan) cameras in an 18-site DR screening implementation and evaluation in Moshi, Tanzania. Although this study is still in progress, interim data has indicated good agreement between DR grading of images acquired by general clinical staff with a conventional fundus camera and Peek Retina when both are performed under dilation (Mwanansao C, et al., unpublished manuscript).

Given that systematic DR screening in Sub-Saharan Africa is presently rarely available, the prospect of implementing an effective programme in a highly

challenging environment such as the Kilimanjaro region is most exciting. If the full results are to replicate those initially being indicated, then this will lend strong supporting evidence for the effectiveness of smartphone-based systematic DR screening.

## Discussion

Despite their immense potential, thus far a very low proportion of the relatively numerous mHealth technology pilot studies conducted have gone on to achieve full integration into healthcare systems [44]. A variety of reasons for this have been noted including failure to keep pace with the rapidly developing mobile phone sector, failure to recognise design decisions which affect the workflow and the need for better coordination between technologists, clinicians and policy makers in developing the common standards and frameworks necessary [45-47].

In these respects smartphone retinal imaging technology is no exception.

With regards to keeping pace with the broader mobile phone market, a functioning screening programme will inevitably require replacement devices during its life. If the technology in use is only compatible with obsolete, and no longer manufactured, handsets then the programme will begin to break down as handsets age and require replacing. Ideally the device would therefore be independent of its host handset. Nevertheless, constant attention will have to be paid by smartphone imaging adapter manufacturers to ensure that their attachments' quality, ease-of-use or even safety are not degraded by developments and trends within the mobile phone sector, or risk becoming obsolete in as little as two to three years after product launch.

The existing published literature relating to smartphone-based DR screening has thus far mostly consisted of ophthalmologists' single-site comparisons to reference standards. This is a vital first step in validating the clinical usefulness of the technology and we commend the robust comparison of smartphone indirect ophthalmoscopy to standard retinal photography by Ryan et al. [34] in particular. However unless the technology can be effectively integrated into the appropriate clinical workflows, where there are non-clinical operators and graders, it cannot be adopted. Additionally new ways of structuring clinical workflows around the technologies have been postulated but there is little peer-reviewed literature showing the impact of these new workflows on patient outcomes. Thus, at present, policy makers are lacking the evidence they need to implement national screening programmes based around mHealth.

To this end, the on-going multi-site trial of Peek Retina and a referral system in Tanzania and its planned expansion to other similar studies in other countries are critically important in establishing the evidence base necessary for smartphone-based systematic DR screening. Developers of smartphone retinal imaging technologies should investigate the effectiveness of these tools within implementable DR screening workflows, with the rigour and scale appropriate for the trialling of any such medical device.

## **Conclusions**

Pilot studies and single-site trials have produced promising results for the validation of smartphone-based DR assessment versus reference standards. However, by nature, the implementation of national, systematic screening programmes is top-down. Continued collaboration across medicine, engineering, healthcare policy and

other disciplines in adapting to local standards and filling gaps in the current literature is required in order to shape national DR strategies. Specifically, more literature describing multi-site trialling, the impact of the technology on the whole clinical workflow, and ultimately the impact on the health outcomes of the screened population are required in order to shape national DR strategies.

## Funding Sources

The authors are in receipt of research funding from The Queen Elizabeth Diamond Jubilee Trust.

The authors received no financial support for the authorship, and/or publication of this article.

## Acknowledgements

None.

## Disclosures

The authors are named inventors on pending patents relating to Peek Retina.

## References

1. Klein R and Klein BEK, Diabetes In America, 2nd ed. Bethesda: National Institute of Diabetes and Digestive and Kidney Diseases; 1995
2. Whiting DR, Guariguata L, Weil C, Shaw J. IDF Diabetes Atlas: Global estimates of the prevalence of diabetes for 2011 and 2030. *Diabetes Research and Clinical Practice*. 2011;94(3):311-321.
3. Wright A and Dodson P. Medical management of diabetic retinopathy: fenofibrate and ACCORD Eye studies. *Eye*. 2011;25(7):843-849.

4. Cheung N, Mitchell P Wong TY. Diabetic retinopathy. *Lancet*. 2010;376(9735):124-136.
5. Lerch C, Richter B, Bergerhoff K, Jousseaume AM. Digital retinal imaging for diagnosing diabetic retinopathy. *The Cochrane Library*. 2011.
6. Fong DS, Aiello L, Gardner TW, et al. Retinopathy in diabetes. *Diabetes care*. 2004;27(suppl 1): s84-s87.
7. Danielsen R, Jonasson F, Helgason T. Prevalence of retinopathy and proteinuria in type 1 diabetics in Iceland. *Acta medica Scandinavica*. 1982;212(5):277-280.
8. Scanlon, PH. The English national screening programme for sight-threatening diabetic retinopathy. *J Med Screen*. 2008;15(1): 1-4.
9. Lowe J. Screening for diabetic retinopathy. *Nursing in General Practice*. 2014.
10. Hautala N, Aikkila R, Korpelainen J, et al. Marked reductions in visual impairment due to diabetic retinopathy achieved by efficient screening and timely treatment. *Acta Ophthalmologica*. 2014;92(6):582-587.
11. Agardh E, Tababat-Khani P. Adopting 3-year screening intervals for sight-threatening retinal vascular lesions in type 2 diabetic subjects without retinopathy. *Diabetes Care*. 2011;34(6):1318-1319.
12. Olafsdottir E, Stefansson E, Biennial eye screening in patients with diabetes without retinopathy: 10-year experience. *British journal of ophthalmology*. 2007;91(12):1599-1601.
13. Kristinsson JK, Stefánsson E, Jónasson F et al. Systematic screening for diabetic eye disease in insulin dependent diabetes. *Acta ophthalmologica*. 1994;72(1):72-78.



14. Kristinsson JK, Hauksdóttir H, Stefánsson E, et al. Active prevention in diabetic eye disease. *Acta Ophthalmologica Scandinavica*. 1997;75(3):249-254.
15. Peto T, Tadros C, Screening for diabetic retinopathy and diabetic macular edema in the United Kingdom. *Current diabetes reports*. 2012;12(4):338-345.
16. City & Guilds. Diabetic Retinopathy Screening. Available at: <http://www.cityandguilds.com/qualifications-and-apprenticeships/health-and-social-care/health/7360-diabetic-retinopathy-screening>. Accessed August 16, 2015.
17. Leese GP, Ahmed S, Newton RW, et al. Use of mobile screening unit for diabetic retinopathy in rural and urban areas. *BMJ*. 1993;306:187-189.
18. Liew G, Michaelides M, Bunce C, A comparison of the causes of blindness certifications in England and Wales in working age adults (16–64 years) 1999–2000 with 2009–2010. *BMJ Open*. 2014;4(2).
19. Fleming AD, Goatman KA, Philip S, et al. Automated grading for diabetic retinopathy: a large-scale audit using arbitration by clinical experts. *British Journal of Ophthalmology*. 2010.
20. Philip S, Fleming AD, Goatman KA, et al. The efficacy of automated “disease/no disease” grading for diabetic retinopathy in a systematic screening programme. *British Journal of Ophthalmology*. 2007;91(11):1512-1517.
21. Burgess PI, Msukwa G, Beare NA. Diabetic retinopathy in sub-Saharan Africa: meeting the challenges of an emerging epidemic. *BMC Medicine*. 2013;11(1):157.

22. Bernardes R, Serranho P, Lobo C. Digital ocular fundus imaging: a review. *Ophthalmologica*. 2011;226(4):161-181.
23. Prasad S and Roy B. Digital photography in medicine. *Journal of postgraduate medicine*. 2003;49(4):332.
24. Armed Forces Supply Support Center. *Military Standard Photograph Lenses*. 1959.
25. International Standards Organisation. *Ophthalmic Instruments: Fundus Cameras*. 2009.
26. Bastawrous A. and Armstrong MJ. Mobile health use in low- and high-income countries: an overview of the peer-reviewed literature. *Journal of the Royal Society of Medicine*. 2013;106(4):130-142.
27. The Nielsen Company. *The Digital Consumer Report Feb 2014*. 2014.
28. d4. *A Survey of Mobile Phone Usage by Health Professionals in the UK*. 2010.
29. Pew Research Center. *Emerging Nations Embrace Internet, Mobile Technology*. 2014.
30. Barsam A, Bhogal M, Morris S, Little B. Anterior segment slitlamp photography using the iPhone. *J Cataract Refract Surg*. 2010;36(7):1240-1241.
31. Gurram, MM. Ophthalmic cell-phone imaging system: a costless imaging system. *Can J Ophthalmol*. 2013;48(5): e135-139.
32. Lord, RK, Sha VA, San Filippo AN, Krishna R. Novel Uses of Smartphones in Ophthalmology. *Ophthalmology*. 2010;117(6):1274-1274.e3.
33. Bastawrous A. Smartphone Fundoscopy. *Ophthalmology*. 2012;119(2):433-433e2

34. Ryan M.E., Rajalakshmi R, Prathiba V, et al. Comparison Among Methods of Retinopathy Assessment (CAMRA) Study: Smartphone, Nonmydriatic, and Mydriatic Photography. *Ophthalmology*. Forthcoming 2015.
35. Myung D, Jais A, He L, et al. 3D Printed Smartphone Indirect Lens Adapter for Rapid, High Quality Retinal Imaging. *J Mobile Tech in Med*. 2014;3(1):9-15.
36. Hong SC, 3D printable retinal imaging adapter for smartphones could go global. *Graefe's Archive for Clin and Experimental Ophthalmology*, 2015: p. 1-3.
37. Welch Allyn Inc. *iExaminer - Eye Imaging on Your iPhone*. Available at: <http://www.welchallyn.com/en/microsites/iexaminer.html>. Accessed August 18, 2015.
38. MediSave Ltd. *Welch Allyn iExaminer Adaptor For iPhone 4 & 4S*. Available from: <http://www.medisave.co.uk/welch-allyn-iexaminer-iphone-adaptor.html>. Accessed August 18, 2015.
39. Giardini ME, Livingstone AT, Jordan S, et al. A smartphone based ophthalmoscope. In: *Proc 36th Annual International Conference IEEE Engineering in Med and Biology Soc*; 2014 Aug 26-30; Chicago, IL. Red Hook, NY: Curran Associates; 2014. 2177-2180
40. Russo A, Civili PS. A Novel Device to Exploit the Smartphone Camera for Fundus Photography. *J Ophthalmology*. 2015.
41. Russo A, Morescalchi F, Costagliola C, et al. Comparison of smartphone ophthalmoscopy with slit-lamp biomicroscopy for grading diabetic retinopathy. *Am J of Ophthalmology*. 2015;159(2):360-364. e1.
42. Bastawrous A, Mathenge W, Peto T, et al. The Nakuru eye disease cohort study: methodology & rationale. *BMC Ophthalmology*. 2014;14(1):60.

43. Bastawrous A, Giardini ME, Bolster NM, et al. Agreement of a Smartphone based ophthalmoscope (Peek Retina) with standard fundus cameras for optic nerve imaging in a large Kenyan cohort. *JAMA Ophthalmology*, Forthcoming 2015.
44. Qiang CZ, Yamamichi M, Hausman V, et al. Mobile applications for the health sector. Washington DC: World Bank; 2012.
45. Kay M, Santos J, Takane M. mHealth: New horizons for health through mobile technologies – volume 3. Geneva: World Health Organization; 2011
46. Kumar S, Nilsen WJ, Abernethy A, et al. Mobile health technology evaluation: the mHealth evidence workshop. *Am J of Preventive Med*. 2013;45(2):228-236.
47. Tomlinson M, Rotheram-Borus MJ, Swartz L, Tsai AC. Scaling up mHealth: where is the evidence? *PLoS Med*. 2013;10(2):e1001382.
48. Buam I. *USAF-1951*. Available at: <https://commons.wikimedia.org/wiki/File:USAF-1951.svg>. Accessed August 30,2015.

## Figures and Figure Legends

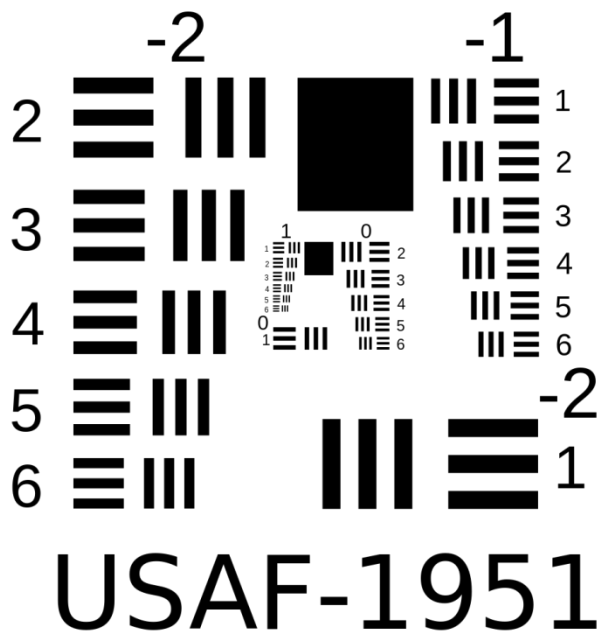


Figure 1 - USAF 1951 resolution test chart (not to scale). The resolving power of an optical imaging system is found according to the group and element of the smallest three line pattern that can be resolved, according to the equation:  $resolution = 2^{group+(element-1)/6}$ . For example the bottom-left target corresponds to 0.445 lp/mm and the top-right target corresponds to 0.500 lp/mm. Reproduced with permission from [48].

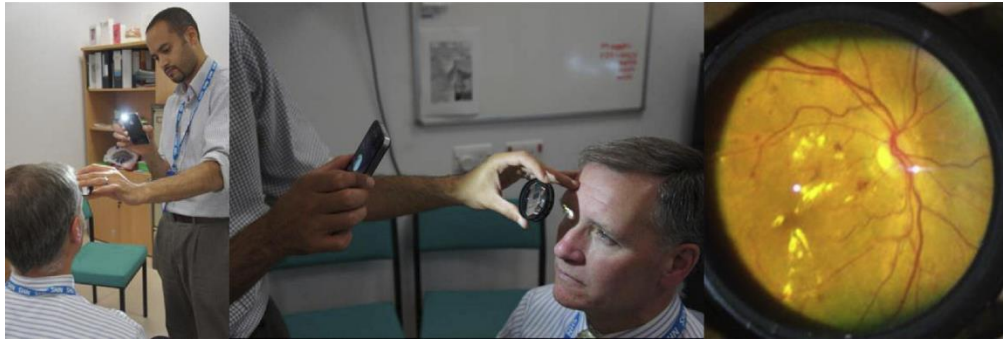

Figure 2 - Imaging the fundus can be achieved by positioning a 20D lens between the eye and the smartphone optic (left and centre). Although diabetic macular edema, for example, can be imaged using this technique (right), it has been reported that insufficient sensitivity is achieved when the technique is integrated into the screening workflow [34]. Left and centre panel reproduced with permission from [33], right panel reproduced with permission from [34].

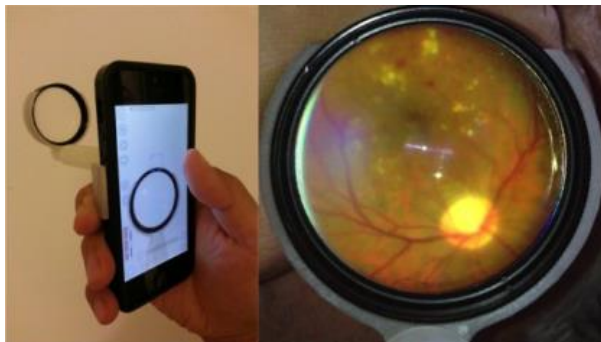


Figure 3 –The 3d printed smartphone retinal adapter for monocular indirect ophthalmoscopy developed by Myung et al. [35] on an iPhone 5 (Apple Inc.) (left). Diabetic macular edema can be photographed using this lens-to-phone mount (right). Reproduce with permission from [35].

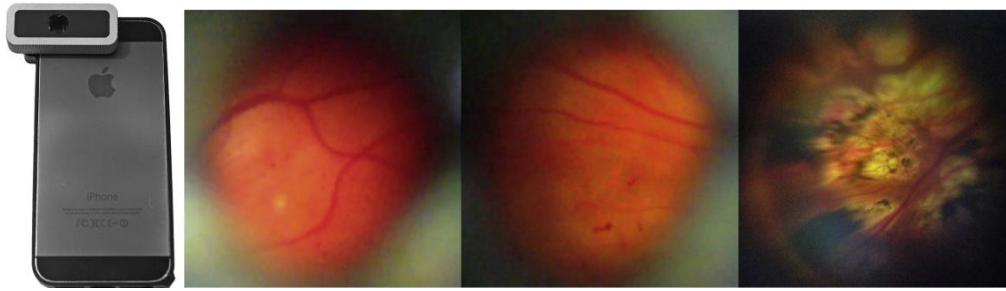


Figure 4 – Example mydriatic retinal images taken with the ‘D-Eye’ on iPhone 6 (far left). Mild nonproliferative diabetic retinopathy (second from left), moderate nonproliferative diabetic retinopathy (second from right) and panretinal photocoagulation scars on a retina with proliferative diabetic retinopathy (far right). Reproduced with permission from [41].

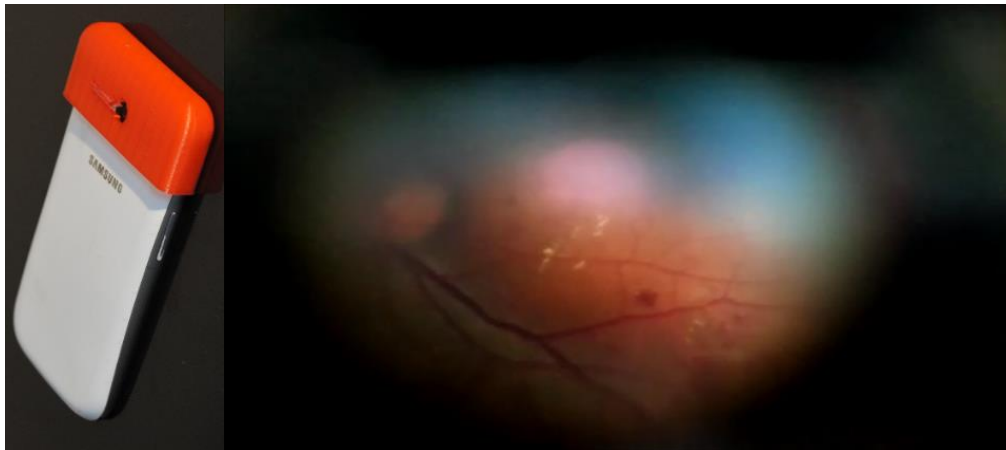


Figure 5 – The pre-production prototype of ‘Peek Retina’ on a Samsung S3 (left) uses a prism to project a light beam which is closely aligned to camera optical axis. It is currently being trialled alongside reference standards in a diabetic retinopathy study in Moshi, Tanzania (frame of captured video, right).