

Spatiotemporal patterns of epiphyseal bone loss after spinal cord injury – an investigation using peripheral Quantitative Computed Tomography (pQCT)

Sylvie Coupaud^{1,2}, Alan McLean², Mariel Purcell², Matthew Fraser², David Allan²

1. Department of Biomedical Engineering, University of Strathclyde, Glasgow UK
2. Queen Elizabeth National Spinal Injuries Unit, Southern General Hospital, Glasgow, UK

OBJECTIVES: This paper describes spatial and temporal distributions of bone loss in the paralysed limbs of patients during their first year after spinal cord injury (SCI). The objectives are to illustrate the intersubject variability in spatiotemporal patterns of bone loss after SCI, and to explore the potential factors affecting them.

METHODS: Twenty-six inpatients of the Queen Elizabeth National Spinal Injuries Unit in Glasgow with a motor-complete SCI leading to paraplegia or tetraplegia were scanned using pQCT within 5 weeks of injury. Scans were repeated at 4, 8 and 12 months post-injury. Two epiphyseal scans were taken in the lower leg, at 4% (distal) and 96% (proximal) of total bone length, and another at the distal femur (4%).

RESULTS: The different spatial patterns of epiphyseal bone loss include a “centralised” or “diffuse” pattern, versus a “speckled” or “mottled” pattern. An example of the pQCT time series at the distal tibia, for a patient exhibiting speckled/mottled bone loss, is given in Figure 1.

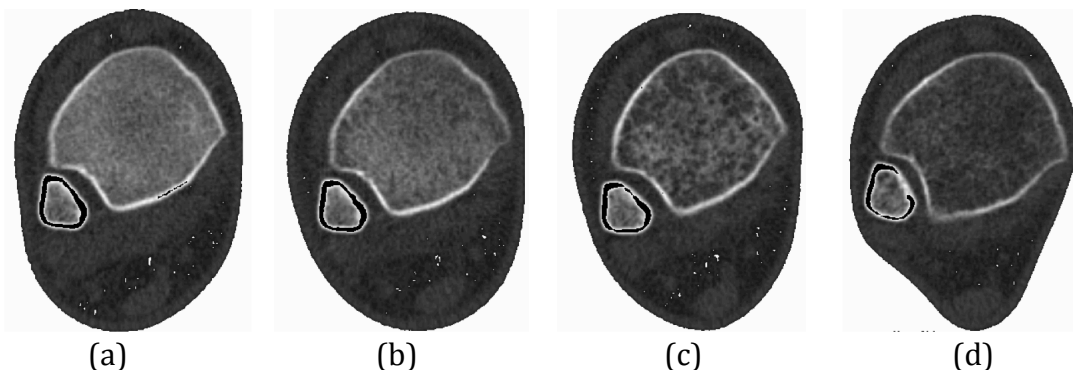


Figure 1: pQCT time series at the distal L tibia (4% of total bone length), at: (a) Baseline (<5 weeks) (b) 4 months (c) 8 months and (d) 12 months post-SCI; Images are for a male patient with motor-complete SCI.

The intersubject variability in temporal patterns of bone loss suggests that some patients exhibit “fast” and others “slow” bone loss. An example of the pQCT time series at the distal tibia, for a patient exhibiting slow bone loss, is given in Figure 2.

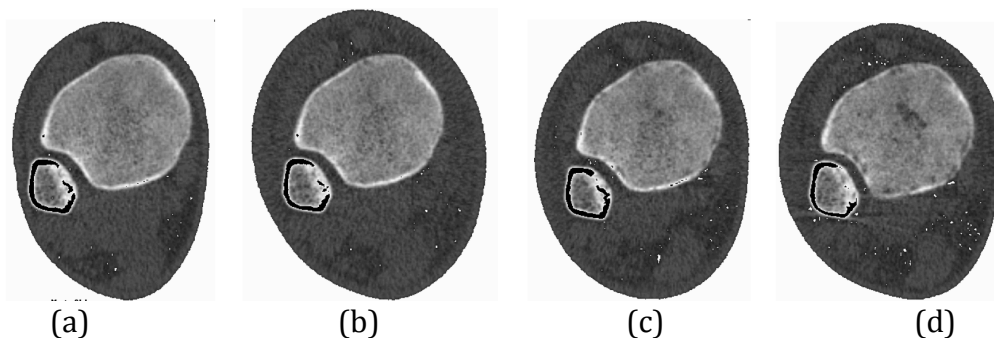


Figure 2: pQCT time series at the distal L tibia (4% of total bone length), at: (a) Baseline (<5 weeks) (b) 4 months (c) 8 months and (d) 12 months post-SCI; Images are for a male patient with motor-complete SCI.

CONCLUSIONS: Different spatiotemporal patterns of bone loss can be identified early after SCI, but further work is needed to identify factors affecting them, and to use spatiotemporal pattern classification to inform the development of new early treatments against further bone loss.